

Yasmine Atteya El Fiky, MD
Yehia Omar, MD
Misr Radiology Center, Cairo, Egypt



BACK GROUND

Prostate cancer is one of the most common cancers among men. The over expression of the prostate specific membrane antigen (PSMA) in prostate cancer helps in the detection of the primary as well as the metastatic lesions of cancer prostate. Recently, in nuclear medicine, we can target the PSMA receptor for diagnostic and therapeutic purposes.

OBJECTIVES



The **evolving** role of PSMA-positron emission tomography-computed tomography (PET/ CT) using the PSMA targeted radiotracer is very important in initial staging, biochemical recurrence, monitoring the therapeutic responses as well as an eligibility tool to select patients that can benefit from radio-ligand therapy (RLT).

METHODS AND RESULTS

This a retrospective descriptive study that include patients with pathologically diagnosed intermediate to high risk prostate cancer. The results from the present study and previous studies provide consistent evidence that the using of PSMA-PET/CT as noninvasive imaging tool can aid health care providers in diagnosis and assessing prostate cancer

Initial staging

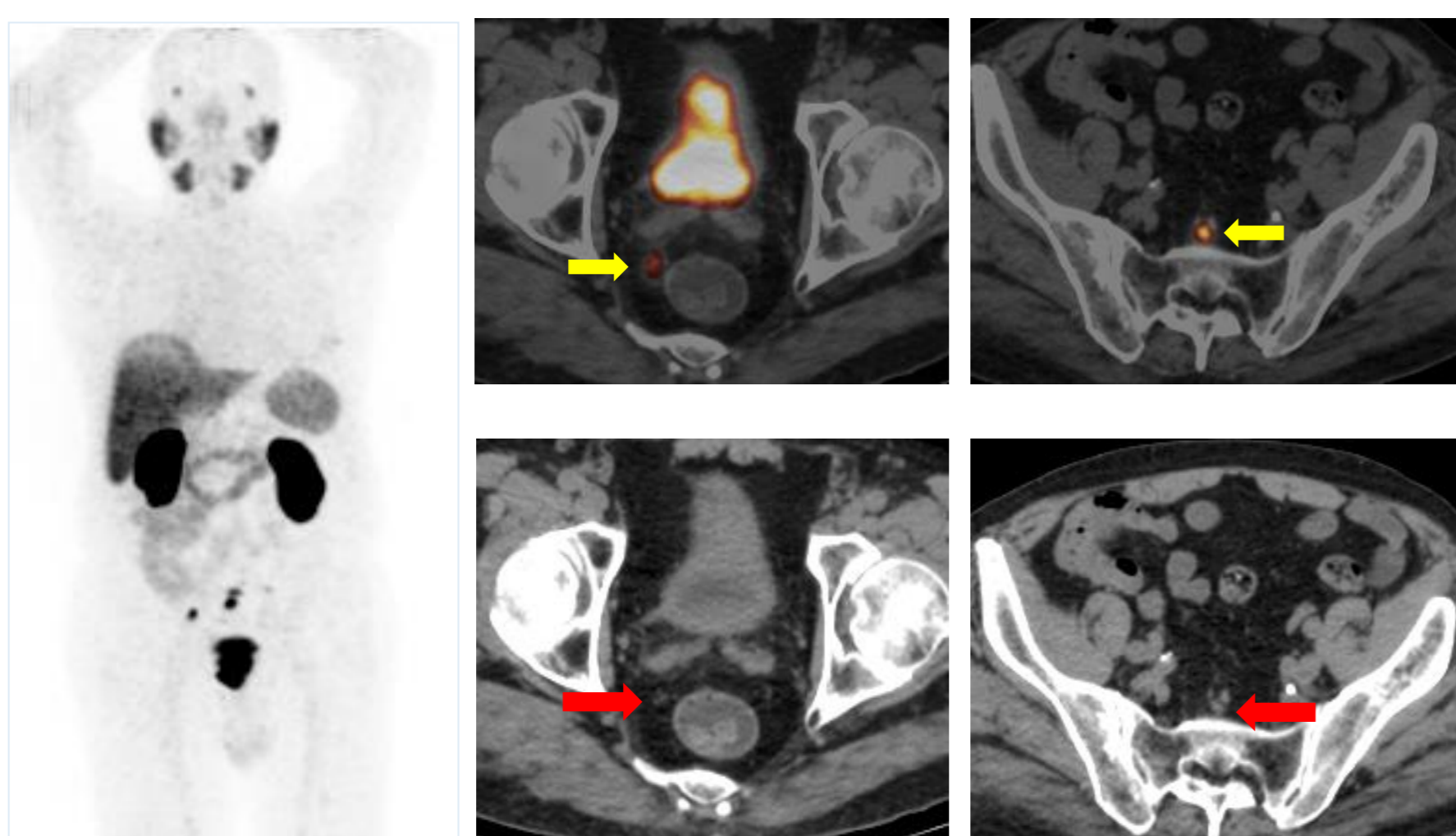


Fig.1: ⁶⁸Ga-PSMA PET/CT showing tiny regional pelvic nodal deposits, that are hardly seen in the CT part of the scan, leading to upstaging of the patient.

Biochemical recurrence

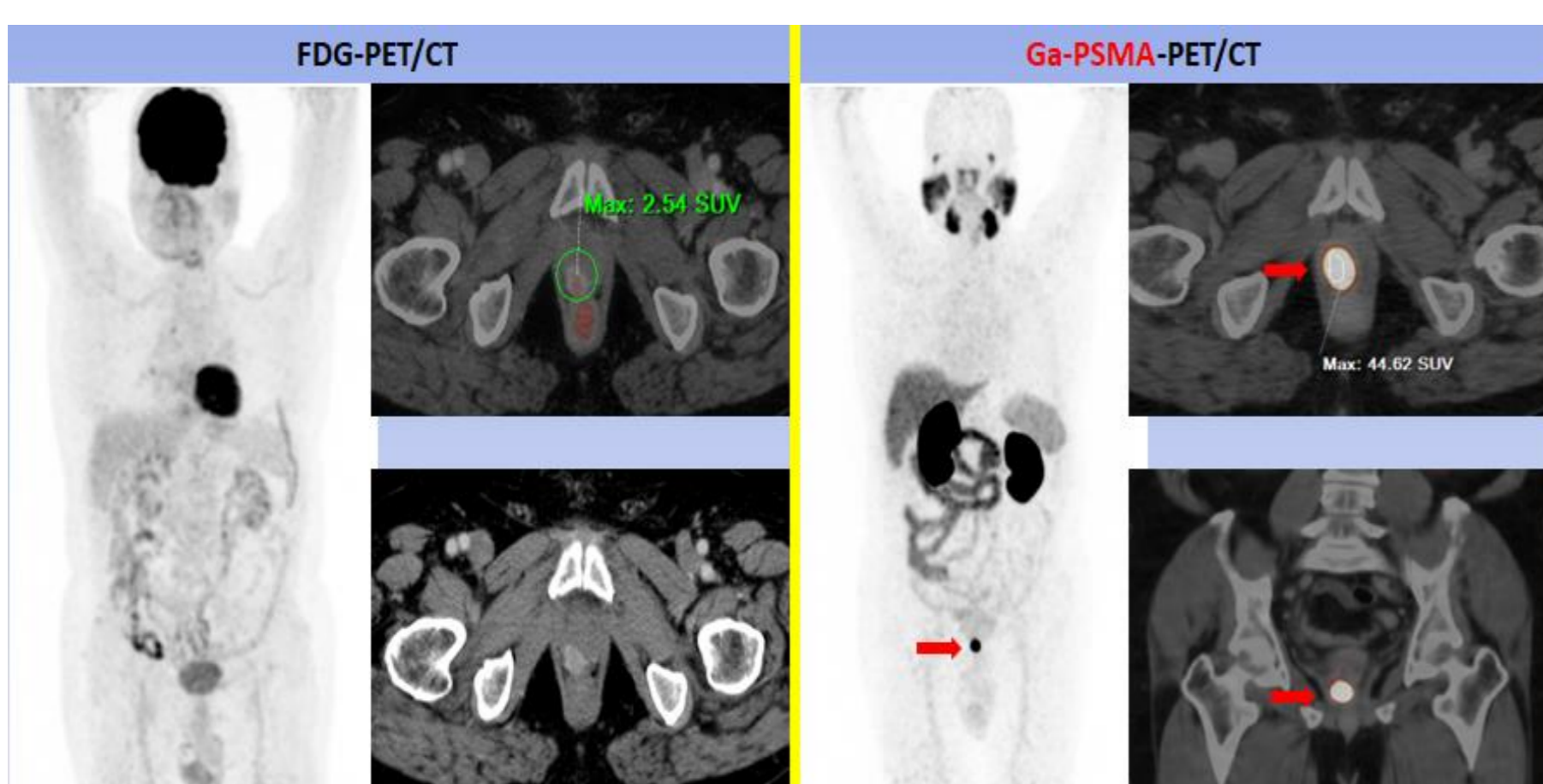

Fig.2: ⁶⁸Ga-PSMA PET/CT Vs ¹⁸F-FDG PET/CT in detecting local operative bed recurrent prostatic neoplasia.

The mass showed low SUVmax values of 2.54 in FDG-PET/CT scan, compared to high value of 44 SUVmax in the PSMA-PET/CT.

Therapy monitoring

Previous scan Current scan

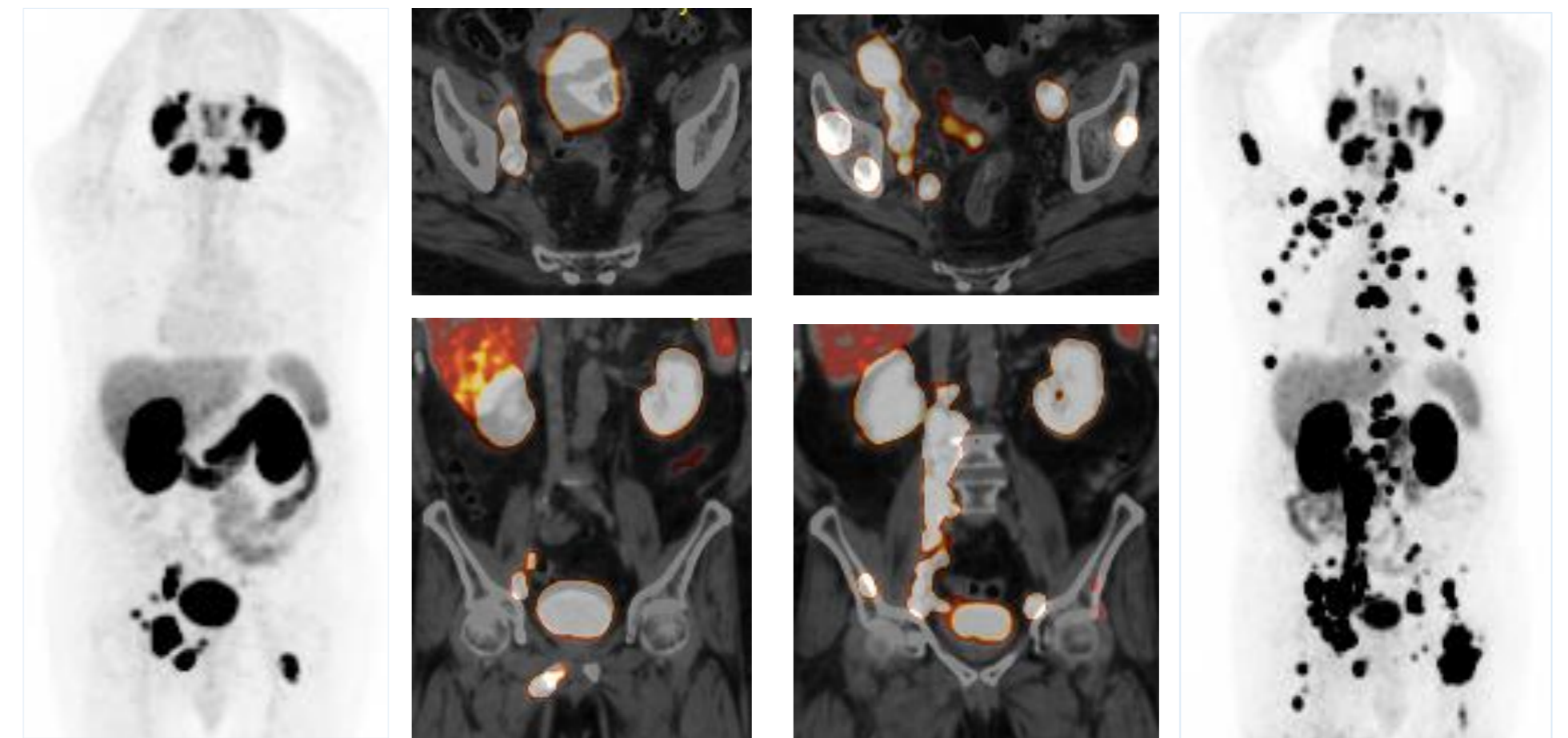


Fig.3: A 68-year-old metastatic cancer prostate, presented with PSA progression and increased bony pains post chemotherapy.

Follow up ⁶⁸Ga-PSMA PET/CT showed progressive course of the disease with multiple newly developed lesions.



One of the most recent and important roles of the PSMA-PET/CT being used as selective tool for the eligibility criteria in patients suitable for radio-ligand therapy (RLT) as well as post therapeutic monitoring and follow up .

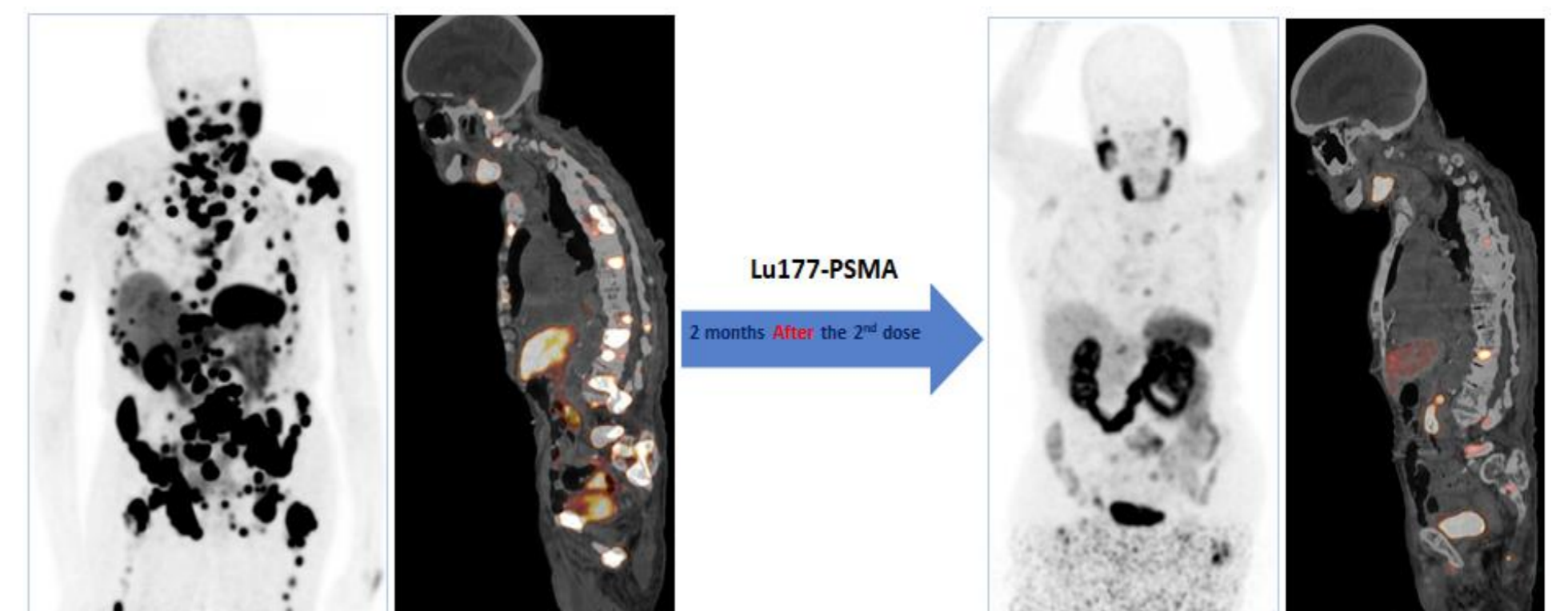


Fig.4: A 95-year-old patient with metastatic castration-resistant prostate cancer (mCRPC), received two doses of the ¹⁷⁷Lu-PSMA at our Theranostic unit. His PSA values dropped from 664 ng/ml to 13 ng/ml in 6 months.

⁶⁸Ga-PSMA PET/CT before and after scans, showing marked regression in the osseous and nodal deposits.

CONCLUSION

PSMA-PET/CT is an evolving imaging modality and game changer with marked impact on patient management planes, playing an important role in changing the patient management with impact in initial staging, biochemical recurrence, treatment response and in selecting patients suitable for Lutetium PSMA Radio-Ligand Therapy (RLT).

REFERENCES

1. Sina H., Courtney Lawhn-Heath and Spencer B.: PSMA PET imaging in the diagnosis and management of prostat Cancer: Abdominal Radiology (2023) April (48):3610–3623.
2. Neal A. Patel and Robert E. Reiter: Impact of a Novel Molecular Imaging Modality, Prostate-Specific Membrane Antigen Positron Emission Tomography, on the Management of Prostate Cancer Journal of Clinical Oncology (2022) Jan (40):13
3. Keidar Z., et al: ⁶⁸Ga-PSMA PET/CT in prostate cancer patients – patterns of disease, benign findings and pitfalls. Cancer Imaging (2018) 18:39
4. Palot F., et al: Gallium-68 Prostate-Specific Membrane Antigen Positron Emission Tomography: A Practical Guide for Radiologists and Clinicians. Cureus (2022) March (14):3
5. Schuchardt C., et al: Prostate-Specific Membrane Antigen Radiolig and Therapy Using ¹⁷⁷Lu-PSMA I&T and ¹⁷⁷Lu-PSMA-617 in Patients with Metastatic Castration-Resistant Prostate Cancer: Comparison of Safety, Biodistribution, and Dosimetry. J Nucl Med (2022) 63:1199–1207

CONTACT

GET IN TOUCH!
What do you think of this study

[yasmineatiya@gmail.com/](mailto:yasmineatiya@gmail.com)
Phone : +201224609799
oyehiaomar@gmail.com